

DOUBLE EXTERNAL JUGULAR VEIN - A CASE REPORT

Sangeeta .M¹, Sridevi N.S¹, Raja Parthiban², Nandish .C¹, Sanikop M.B.¹

ABSTRACT

Knowledge of the varying drainage patterns of superficial veins of head and neck is not only important for anatomists but also for surgeons operating at this level and to clinicians in general. The variations are also important for interventional radiologists who perform transjugular procedures such as port implantations and intrahepatic portosystemic shunts or selective venous samplings in patients with hyperparathyroidism of unknown origin. Results of recent studies report that the superficial veins especially the external jugular vein have been increasingly used for cannulation to conduct diagnostic and therapeutic procedures. Although studies have been done on variations of veins of head and neck, external jugular vein duplication along the whole length has not been reported so far. We report a very unusual bilateral presentation of external jugular vein duplication along its whole length in an embalmed male cadaver observed during routine dissection. Embryological evaluation of the anomaly was done and compared with the available literature which showed that the observed variation was rare.

Key words: cadaver, facial, jugular, variation

INTRODUCTION

The complex embryological development of the vascular system often results in a myriad of clinically relevant anomalies. Variations in the drainage pattern of the veins of the face have been observed in the past^[1]. The standard anatomical description of the veins of the face is of the superficial temporal vein uniting with the maxillary vein to form the retromandibular vein within the substance of the parotid gland. The retromandibular vein divides into anterior and posterior divisions before emerging from the apex of the gland. The anterior division unites with the facial

vein to form the common facial vein slightly inferior and anterior to the angle of the mandible. The posterior division unites with the posterior auricular vein to form the external jugular vein^[2]. The relevance and importance of varied drainage patterns of the veins of the head and neck warrant attention for their use in surgeries involving micro vascular anastomoses^[3]. External jugular vein has been recommended and routinely used in patients undergoing transjugular liver biopsy as it obviates a deep neck puncture thereby reducing the risk in patients with impaired coagulation.^[4] External jugular vein is easier to visualize than internal jugular vein and gives reliable estimate of central venous pressure.^[5] In addition it is reported that the insertion of a permanent catheter for haemodialysis via external jugular vein is a simple and short procedure with no severe complications.^[6]

CASE REPORT

During routine dissection for undergraduate students in the department of Anatomy, SDUMC, Kolar an unusual pattern of venous drainage was noted in a middle aged male cadaver. Two external jugular veins were seen crossing the sternocleidomastoid on both sides. On both sides, one of the jugular veins was formed as the continuation of the common trunk formed by the union of facial vein and submental vein. This external jugular vein was seen to cross the middle of the anterior border of sternocleidomastoid. Retromandibular vein divided within the substance of the parotid into anterior and posterior divisions. Anterior division passed deep to the angle of the mandible and drained into facial vein. Posterior division of the retromandibular vein continued as the second external jugular vein on both sides. Posterior auricular vein was absent on both sides. This second external jugular vein crossed the posterior border of sternocleidomastoid. Both the external jugular veins

¹Department of Anatomy, Sri Devaraj Urs Medical College and Research Centre, Tamaka, Kolar, Karnataka.

²Department of Pathology, M V J Medical College and Research Centre, Hoskote, Karnataka.

united to form a loop which drained into subclavian vein. This pattern was seen bilaterally. This bilateral spectrum of anatomic variation makes it a rare special case.

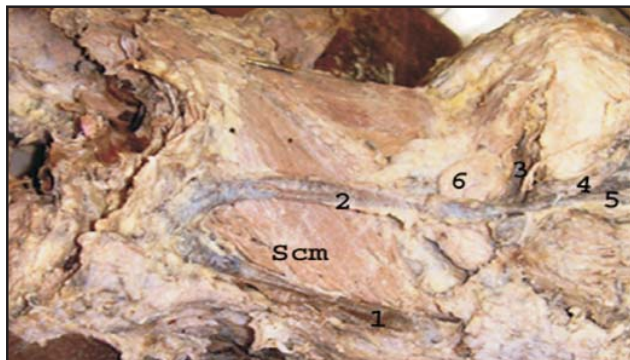


Figure 1. : 1 and 2- External jugular veins, 3 -Submental vein, 4- Facial artery, 5- Facial vein, 6 -Submandibular gland, Scm - Sternocleidomastoid muscle

DISCUSSION

The external jugular veins are so variable that it is not possible to determine a normal pattern. Bergman et al^[7] have reported the following variations of external jugular vein: It may be formed merely by the posterior auricular vein, and on occasion it receives the facial, lingual and cephalic veins. It may pass over the clavicle and open into the cephalic, subclavian, or internal jugular veins. The vein may be sometimes doubled. The external jugular vein may descend posterior to the inferior belly of omohyoid. In some cases it forms an annulus around the clavicle.

A case of facial vein uniting with retromandibular vein at a higher level in parotid gland was observed by Kopuz et al.^[8] Common facial vein draining into external jugular vein was noted in the study by Chowdhary et al with an incidence of 5%.^[9] Prakash et al^[10] reported a case where external jugular vein passed obliquely downwards and laterally at first superficial to sternocleidomastoid and then obliquely downwards and medial deep to it and descended into Internal jugular vein high up at the junction of upper 2/5 and lower 2/5 of the line joining the angle of mandible and middle of clavicle. Hollinshead has described variations of the external jugular vein where the vein ran vertically downwards across the

superficial surface of sternocleidomastoid and very rarely deep to it^[2]. In one third cases it ended in internal jugular vein in its lower part.

Absence of posterior auricular vein has been reported by Sateesha et al but this was associated with undivided retromandibular vein which joined with facial vein to form external jugular vein.^[7]

The veins of the neck vary considerably in their connections with each other. These anomalous patterns differ in their presentation being unilateral or bilateral. In our present case a bilateral variation was observed. As per standard text books of Anatomy, external jugular vein is normally formed by the union of posterior auricular vein and posterior division of retromandibular vein. In our case one of the external jugular veins was formed by the continuation of the common trunk formed by the union of facial vein and submental vein and the other by the continuation of posterior division of retromandibular vein.

EMBRYOLOGICAL HYPOTHESIS

The complex embryological development of the vascular system might often result in clinically important variations as in the present case. The veins draining regions of the face and neck establish their identity after the development of the skull. The external jugular vein is developed from a tributary of the cephalic vein from the tissues of the neck and anastomoses secondarily with the anterior facial vein. The cephalic vein at this stage forms a venous ring around the clavicle from which it is connected with the caudal part of the precardinal vein. The deep segment of the venous ring forms the subclavian vein and receives the external jugular vein. The superficial segment usually dwindles but may persist in adult life. In the present case it can be hypothesized that external jugular vein failed to develop its posterior connections with retromandibular vein, with the persistence of the connection between common facial and precardinal vein as seen in 18 milli meter stage of embryo^[10]

CONCLUSION

To conclude, superficial veins especially external jugular vein are increasingly used for cannulation to conduct

diagnostic procedures or intravenous therapies. Ultrasound guided venipuncture is a viable possibility in cases of variations in patterns of superficial veins and their knowledge is also important for surgeons doing reconstructive surgeries^[12]. These variations are important for surgeons to avoid any intraoperative trial and error in procedures which might lead to unnecessary bleeding. Significance of this anomaly is due to its bilateral occurrence as the same has not been reported in previous literature.

REFERENCES

- 1) Yadav.S, Ghosh S.K, Anand.C. Variations Of Superficial Veins Of Head And Neck. Journal of Anatomical society of India. 2000; 49:61-62.
- 2) Hollindshed W.H. Anatomy For Surgeons. The Head And Neck. New York; Harper and Row. 1968 ;3:530.
- 3) Mehra S ,Kaul J.M and Das S. Unusual Venous Drainage Pattern Of Face, A Case Report. Journal of Anatomical society of India. 2003;52(1);64-65.
- 4) Seigel EL, Caresi OJ, Eckard DA. Use Of The External Jugular Vein In Approach For Transvenous Liver Biopsy. J Vaso Intervent Radiol. 1992; 2(3):371-374.
- 5) Vinayak AG, Levitt J, Gehlbach B, Pohlman AS, Hall JB, Kress JP .Usefulness Of The External Jugular Vein In Detecting Abnormal Central Venous Pressure In Critically Ill Patients. Arch Intern Med 2006; 166(19):2132-2137.
- 6) Skandalos IK , Amvrosiadias DM, Christodoulou ACH, Evangelouin, Ditsias FK ,Karamoshos KN . Catheterization Of The External Jugular Vein For Hemodialysis . Khirurgila (Mosk).2005;11:47-50.
- 7) Satheesha Nayak B , Soumya K.V . Abnormal Formation And Communication Of Jugular Vein .International Journal Of Anatomic Variation.2008;(1): 15-18.
- 8) Kopuz C,Yavuz S ,Cumhurn ,Tetik S, Ilgi S. An Unusual Coursing Of Facial Vein. Kaibogaku Zaishi. 1995;70 (1):20-22.
- 9) Choudhury R,Tuli A,Chowdhry S. Facial Vein Terminating In External Jugular Vein, An Embryological Interpretation. Surg Radiol Anat. 1997; 19:73-77.
- 10) Prakash R, Prabhu LV, Kumar J, Singh G, Variations Of Jugular Veins: Phylogenetic And Clinical Implications. Southern Medical Journ. 2006;1999:1146-114.

NATIONAL JOURNAL OF BASIC MEDICAL SCIENCES

Journal Subscription form

Annual subscription is for four issues of the Journal and is Rs. 3000/- including postage and packing.

Subscriber/ Invoice Details

Title:

First Name:

Last Name:

Designation:

Organisation:

Address:

E-mail:

Telephone:

Fax:

Detail of payment [Cash / Cheque / Demand Draft payable to Society for Basic Medical Sciences, Salem]:

Amount :

Draft No.:

Date:

Bank & Branch Name:

Please send this form to:

Dr. Evangeline Nesa Ratnabai, Editor -in- Chief, NJBMS,

Professor & HOD, Department of Biochemistry,

Vinayaka Mission's Kirupananda Variyar Medical College, Seeragapadi, Salem 636308, Tamil Nadu.