

## Morphometry of Mitral Valve in South Indians - A Cadaveric Study

Irankathir.S<sup>1</sup>, Sulochana Sakthivel<sup>2</sup>

<sup>1</sup>Associate Professor of Anatomy, Aarupadaiveedu Medical College and Hospital, Pondicherry.

<sup>2</sup>Assistant Professor of Anatomy, JIPMER, Puducherry.

### ABSTRACT

**Aim:** Mitral valve is a complex structure and understanding the normal anatomy of mitral valve complex is important for assessing the valve pathologies and also in mitral valve replacement surgery. Thus the present study was done on the morphometry of the mitral valve in formalin fixed human hearts.

**Materials and Methods:** Mitral valve was studied in 50 formalin fixed hearts procured from human cadavers. Circumference of the mitral valve, the length of the attached margin, width and thickness of the anterior and posterior leaflets were measured.

**Results:** Circumference of the mitral valve was 8.29 cm. Length of the anterior leaflet was 3.23 cm and the length of the posterior leaflet was 4.82 cm. Width of the anterior and posterior leaflets were 2.42 cm and 1.28 cm respectively. Thickness of anterior leaflet was 0.76 mm and that of posterior leaflet was 0.43 mm.

**Conclusion:** The present study provides the necessary data on the dimensions of mitral valve, which will be helpful for surgeons as well as in the manufacture of prosthetic valve.

**Keywords:** Mitral valve complex, Anterior leaflet, Posterior leaflet, Prostheses.

### INTRODUCTION:

Mitral valve is a complex structure comprising of supporting annulus, two leaflets, chordae tendineae and papillary muscles. Mitral annulus is an area where muscular fibers of atrium and the ventricle are attached with the two leaflets – anterior and posterior.<sup>1</sup> Chordae tendineae from the papillary muscles are attached to both leaflets of the mitral valve.<sup>1</sup> The posterior leaflet is divided into three scallops (segments) by two indentations which are described as P1 (lateral segment), P2 (central segment), and P3 (medial segment).<sup>2</sup> The

corresponding parts of the anterior leaflet are A1, A2 and A3 segments.<sup>3</sup>

The mitral valve is altered by various disease and disorders viz., stenosis, regurgitation, congenital valve disease, valve prolapse and acquired valve diseases - include infections, infective endocarditis & rheumatic fever and structural valve changes like stretching or tearing of the chordae tendinae, papillary muscles, fibro-calcific degeneration or dilatation of the valve annulus.<sup>4-6</sup> Valve replacement with prosthetic heart valves is required in severe valve damage. Thus understanding the normal anatomy of mitral valve complex is of utmost

#### Address for correspondence:

Dr. Sulochana Sakthivel, Assistant Professor of Anatomy, JIPMER Academic Center, JIPMER, Pondicherry - 605006.  
Ph.No: 9894584185, Email id: sulo.ss@gmail.com

importance for assessing the valve pathologies by imaging modalities, manufacturing prosthetic valves of appropriate dimensions and in surgical correction of damaged heart valves.

Morphological studies of the mitral valve in South Indians are comparatively less and hence, the present cadaveric study is undertaken, due to its clinical importance and to explore morphometry of the mitral valve.

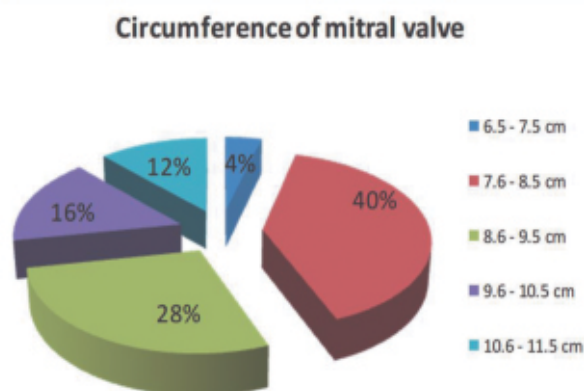
### MATERIAL AND METHODS:

Fifty formalin fixed hearts of either sex procured from cadavers in the age group of 30 - 60 years were included in the study. Cadavers with the history of any cardiac pathology were excluded from the study. Left ventricle was laid open by making an incision on the left margin of the heart, extending up to the apex of the heart and the mitral valve was exposed. After a thorough washing with water, the cusps of the mitral valve were examined. The circumference of the annulus was measured with the help of a thread. The thread was placed along the boundary of the annulus conforming to its shape and is cut where the ends of the thread meet and then measured with a ruler after it is straightened. Digital vernier caliper was used to measure the length, width and thickness of the anterior and posterior leaflets of mitral valve. The dimensions were compared with similar studies in literature.

### RESULTS:

Circumference of the annulus ranged from 6.5 - 11.5 cm. Average circumference of the annulus was found to be 8.29 cm. In 20 specimens (40%), the circumference was in the range of 7.6 - 8.5 cm. In 14 specimens (28%) it was 8.6 - 9.5 cm, and in eight specimens (16%) it was 9.6 - 10.5 cm (Fig.1).

**Figure 1. Circumference of mitral valve in the present study.**



Length of the leaflets was measured at its attached margin. Average length of the anterior leaflet of the mitral valve was 3.23 cm. In 22 specimens (44%), the range was found to be 2.0-3.0 cm and in 28 specimens (56%), it was 3.1-4.0 cm. Average length of the posterior leaflet was 4.82 cm. In 18 specimens (36%) the range was 3.5-4.5 cm and in 32 specimens (64%), it was 4.6-5.5 cm. Mean width of the anterior leaflet from the annulus to the apex was 2.42 cm. In 16 specimens (32%), it was 1.0-2.0 cm and in 34 specimens (68%), width was found to be in the range of 2.1-3.0 cm. Average width of the posterior leaflet was 1.28 cm. In 28 specimens (56%), width was in the range of 1.0-1.5 cm and in 22 specimens (44%), it was 1.6-2.0 cm. Thickness of the middle scallop of the both the leaflets was measured. The mean thickness of anterior leaflet was found to be 0.76 mm. In eight specimens (16%), it ranged from 0.50-0.60 mm, in 18 specimens (36%), it was 0.61-0.70 mm and in 24 specimens (48%), width was found to be in the range of 0.71-0.80 mm. Average thickness of posterior leaflet was 0.43 mm. In eight specimens (16%), it was 0.35-0.40 mm, in 26 specimens (52%), it was 0.41-0.45 mm and in 16 specimens (32%), it was found to be 0.46-0.50 mm.

**Table 1. Circumference of the mitral valve annulus in various studies.**

S. No.	Study	Circumference (cm)
1	Brock <sup>17</sup> 1952	10.5
2	Rusted et al 1952	9.9 (8.5-11.0) Male 8.5 (7.5-10.5) Female
3	Du Plessis et al. 1964	10.1
4	McAlpine 1975	13.4
5	Sakai et al. 1999	9.33 ± 1.1
6	Patil et al. 2009	8.248
7	Gupta et al 2012	9.1 ± 0.44
8	Present study	8.29

**Table 2. Width of mitral valve from annulus to apex in various studies.**

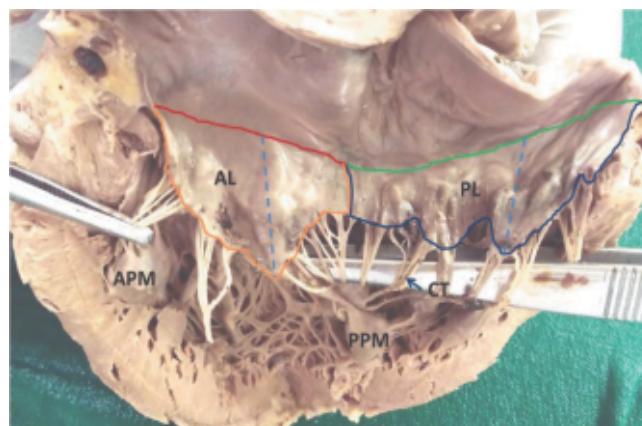
S. No.	Study	Anterior Leaflet (cm)	Posterior Leaflet (cm)
1	Walmsley 1929	1.5 -1.8	1.0 – 1.2
2	Rusted et al.1952	2.20	1.25
3	Morris 1960	2.7	1.75
4	Pant 2013	2.16	1.3
5	Mishra et al 2014	2.11 (1.11 – 3.74)	1.52 (0.62 -2.55)
6	Present study	2.42	1.28

**DISCUSSION:**

Mitral valve is a complex structure and understanding the normal anatomy of mitral valve is of clinical importance for assessing the valve pathologies and thus this study was undertaken (Fig-1). Circumference of the mitral valve (mean = 8.29 cm) in the present study corresponds with the values in the study by Patil et al.<sup>8</sup> (mean - 8.248 cm), but significantly lower than the values in the studies by Mc Alpine<sup>9</sup> and Du Plessis et al.<sup>10</sup> (Table1). Gupta et al.<sup>7</sup> found in their study that in 57% of the cases, the circumference of mitral valve was in the range of 8 - 10 cm (mean: 9.11 cm) but their study included 18 adult cadaveric hearts whereas Mishra

et al.<sup>11</sup> in their study on 120 cadaveric hearts found that the circumference of the mitral valve was between 7.5 and 10 cm (mean: 8.7 cm) in 55.83% of specimens. In the present study, the range was 7.6 - 8.5 cm in 40% of the cases (Fig 2).

**Figure 2. Mitral valve**



**Red & Green lines:**

Attached margins of Anterior and Posterior leaflets. Blue lines: Width of leaflets. AL - Anterior Leaflet, PL - Posterior Leaflet, CT - Chorda Tendinae, APM - Anterior Papillary Muscle, PPM - Posterior Papillary Muscle.

Du plessis et al.<sup>10</sup> reported that the annular attachment of the anterior cusp is half that of the posterior cusp. In present study, length of the attached margin of anterior leaflet was 3.23 cm and posterior leaflet was 4.82 cm. The length of the leaflet from the annulus to apex is also described in many studies as the width or the height of the leaflets. In a study<sup>12</sup> done in India, the mean length of the anterior and posterior leaflet was 2.16 cm and 1.75 cm respectively. In another study<sup>13</sup>, the range of the length of the anterior leaflet was 1.5 – 1.8 cm and that of the posterior leaflet was 1.0 -1.2 cm. In present study, the average width of anterior leaflet (2.2 cm) and posterior leaflet (1.28 cm)

corresponds with that of Morris<sup>14</sup>, Pant et al.<sup>12</sup> and Rusted et al.<sup>3</sup> but differs from that of Walmsley<sup>13</sup> and Mishra et al.<sup>11</sup> (Table 2).

Sahasakul et al.<sup>15</sup> in their study on three age groups (less than 20, 20 to 59 and  $\geq$  60 years) found the thickness of anterior leaflet to be 1.30, 1.60 and 3.20 mm and those for the posterior mitral leaflet to be 0.91, 1.13 and 2.04 mm respectively. Mean thickness of the middle scallops of the anterior and posterior leaflets in the present study was 0.7 and 0.4 mm respectively.

The mitral valve is damaged by various disease and disorders which could be congenital or acquired.<sup>4-6</sup> Valve replacement is required in severe valve damage. In valve replacement surgery, the mitral valve is replaced with mechanical valve or biological (tissue) valve.<sup>7</sup> Tissue valve could be allograft, autograft or xenograft.<sup>7</sup> Allograft is procured from human cadaveric valves whereas autograft is from the patients' pulmonary valve, fascia lata or pericardium. Xenograft could be a porcine mitral valve or bovine pericardium.

Congenital mitral valve malformations are treated by mitral valve repair or replacement with mechanical prostheses. Tissue valves are contraindicated in children because of premature tissue degeneration.<sup>16</sup> When mitral valve repair is not possible in children, implantation of mitral valve prosthesis is postponed till annular growth is achieved.<sup>16</sup> Accurate knowledge about the normal anatomy of the mitral valve complex is needed in assessing the valve pathology and in the selection of valve prostheses.

## CONCLUSION:

Circumference of the mitral valve was 8.29 cm. Length of the attached margin, width and thickness

of the anterior leaflet of mitral valve 3.23 cm, 2.42 cm and 0.76 mm, respectively and that of the posterior leaflet were 4.82 cm, 1.28 cm and 0.43 mm, respectively. Normal function of the mitral valve complex depends on the function of the leaflets, annulus, chordae tendineae and papillary muscles<sup>2</sup>. Accurate knowledge about the anatomical features of the mitral valve is essential for assessing the mitral valve pathology and in construction of prosthesis for valve replacement. We hope that the present study in the South Indians confers proper guidance in the mitral valve replacement surgery as well as in the manufacture of prosthetic valves.

## REFERENCES:

1. Standring S. Gray's Anatomy: The Anatomical Basis of Clinical Practice. 41st Ed, Elsevier Limited, New York, 2016; pp 1008-10.
2. Ginghină C, Vlădaia A, Ghiorghiu I, Serban M, Popescu BA, Jurcuț R. Echocardiography in congenital mitral valve regurgitation—the liaison between cardiologist and surgeon. J Med Life. 2009;2(4):407–413.
3. Lancellotti P, Moura L, Pierard LA, Agricola E, Popescu BA, et.al. European Association of Echocardiography recommendations for the assessment of valvular regurgitation. Part 2: mitral and tricuspid regurgitation (native valve disease). Eur J Echocardiogr 2010;11:307 - 332.
4. Rusted IE, Schiefley CH, Edwards JE. Studies of the mitral valve I. Anatomic features of the normal mitral valve and associated structures. Circulation. 1952; 6:825–31.
5. Sakai T, Okita Y, Ueda Y, Tahata T, Ogino H, Matsuyama K. Distance between mitral

- annulus and papillary muscles: Anatomic study in normal human hearts. *Journal of Thoracic Cardiovascular Surgery*. 1999; 118:636–40.
6. Bhandari S, Subramanyam K, Trehan N. Valvular Heart Disease: Diagnosis and Management. *J Assoc Physicians India*. 2007; Aug; 55:575-84.
  7. Gupta C, Shetti VR, Manju BVM. Dimensions of the human adult mitral valve in the embalmed cadaver. *Journal of Morphological Science*, 2013, vol. 30(1): 6-10.
  8. Patil D. Mehta C. Prajapati P. Morphology of Mitral valve in Human cadavers. *Internet Journal of Cardiology*. 2009; vol. 7(2): 2043-50.
  9. Mc Alpine WA. The Mitral Valve, In: *Heart and Coronary Arteries*. Springer, New York, 1975; pp 52-56.
  10. Du Plessis LA, Marchand P. The anatomy of the mitral valve and its associated structures. *Thorax*, 1964, vol. 19(3):221-7.
  11. Mishra PP, Rao MP, Paranjape V, Kulkarni JP. Morphometry of Mitral valve. *Medical Journal of Dr. D.Y. Patil University*. 2014; Vol 7(5):625-630.
  12. Pant P, Mukhia R, Kumari HN, Mukherjee A. Morphological and morphometric analysis of mitral valve in Maharashtra region: Cadaveric study. *Indian J Appl Res* 2013;3:497-8.
  13. Walmsley T. The heart. In: Sharpey-Schafer E, Symington J, Bryce TH, editors. *Quain's Elements of Anatomy*, vol 4, 11th Ed., London: Longmans, Greens and Co. 1929; p. 42.
  14. Morris E.W.T., Some features of the mitral valve; *Thorax*, 1960; 15;70:22.
  15. Sahasakul Y, Edwards WD, Naessens JM, Tajik AJ. Age-related changes in aortic and mitral valve thickness: implications for two-dimensional echocardiography based on an autopsy study of 200 normal human hearts. *Am J Cardiol*. 1988;62(7):424-30.
  16. Oppido G, Davies B, McMullan DM et al. Surgical treatment of congenital mitral valve disease: Midterm results of a repair-oriented policy. *J Thorac Cardiovasc Surg* 2008; 135(6): 1313 – 1321.
  17. Brock RC. The surgical and pathological anatomy of the mitral valve. *Br Heart J* 1952;14:489-513.

Received on 12/07/2017 Revised on 28/08/2017 Accepted on 31/08/2017