

## MANAGEMENT OF CUTANEOUS LEIOMYOMATOSIS IN REED'S SYNDROME : A RARE CASE REPORT

Venna Ashok.b<sup>1</sup>, Panigrahi Sudhir.K<sup>2</sup>, Sri Venkateshwaran.K<sup>3</sup>, Selvakumar.M<sup>4</sup>, V. Ashok Babu<sup>5</sup>,

### ABSTRACT

Reed's syndrome or familial leiomyomatosis cutis et uteri is a rare syndrome. A 45 year old female presented to the dermatology out-patient department with multiple painful, raised skin lesions over the right upper arm and solitary lesions on right forearm, right upper thigh and upper back of seven years duration. On examination, tender, multiple, reddish brown papulonodular lesions in a cluster over the upper arm and discrete over the forearm, thigh and back were noticed. Excisional biopsy of a solitary lesion revealed piloleiomyoma. Past history revealed total abdominal hysterectomy nine and half years back for fibroid uterus. Family history revealed complaints of similar solitary lesions in her son and daughter. Patient was offered excision and primary skin grafting. The rarity of this syndrome and cutaneous leiomyoma are discussed.

**Key words:** Reed's syndrome, cutaneous leiomyoma familial, hysterectomy, fibroid uterus.

### INTRODUCTION

Reed's syndrome or familial leiomyomatosis cutis et uteri is a rare disorder of multiple piloleiomyomas with uterine smooth muscle tumor.<sup>[1]</sup> We present a case of multiple cutaneous leiomyomas in a 45 year old female with past history of hysterectomy and a positive family history of leiomyomas in her son and daughter. The purpose of the report is because of its rarity and rationale for the study is to document the management and outcome (recurrence).

### CASE REPORT

A 45 year old female presented with painful raised lesions

over the right arm, forearm, upper thigh and back of 7 yrs duration. Patient was asymptomatic 7 yrs before, then she noticed few raised lesions initially over the right arm, which were gradually increasing in size and number and were also spreading to the forearm, thighs and back. She gives history of spontaneous pain over the lesions, especially when exposed to cold, in winter and rainy season. She also gives history of similar solitary lesions in her son and daughter who underwent surgical excision with biopsy report of piloleiomyoma. The patient had undergone hysterectomy for leiomyoma of the uterus being troubled by dysfunctional uterine bleeding.

On examination multiple papulonodular lesions noticed over the extensor aspect of right arm (Figure 1) with solitary nodular lesion over the forearm, thigh and back. Ice cube test was made by exposing the lesions to ice cube and they were painful on exposure to cold. A provisional diagnosis of leiomyoma and differential diagnosis of angiolipoma, nevus, glomus tumor, neurofibroma, lipoma were offered.

After admission, she was investigated. Vitals complete blood count, basic renal profile, blood sugar were found within normal limits. Ultrasound of abdomen and pelvis revealed absent uterus and normal appearing kidneys. After obtaining anaesthesia fitness, she was subjected to excision of all the lesions and split skin graft over right arm site (figure 2). Histopathology from the excised lesions revealed interlacing bundles of spindle shaped cells with cigar shaped nuclei amidst adnexal structures and adipocytes suggestive of piloleiomyoma. (Figure 3,4,5,)

<sup>1</sup>Assistant Professor, Department of DVL, Vinayaka Missions Medical College & Hospital - Karaikal

<sup>2</sup>Associate Professor, Department of General Surgery, Vinayaka Missions Medical College & Hospital - Karaikal

<sup>3</sup>Professor, Department of DVL<sup>1</sup> Vinayaka Missions Medical College & Hospital - Karaikal

<sup>4</sup>Associate Professor, Department of General Surgery, Vinayaka Missions Medical College & Hospital - Karaikal

<sup>5</sup>Department of Dermatology, Venereology & Leprosy (DVL) & General Surgery, Vinayaka Missions Medical College & Hospital - Karaikal

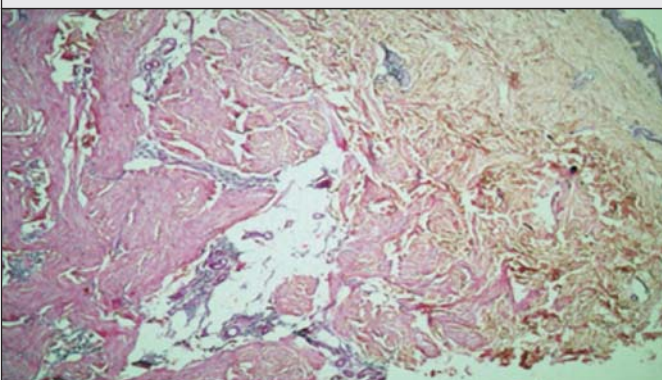
Figure - 1 : Multiple Skin Nodules - Right Arm

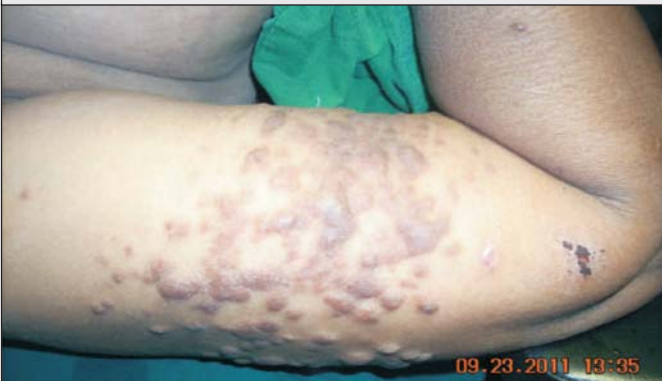

Figure - 2 : Split Skin Graft Over Lesion

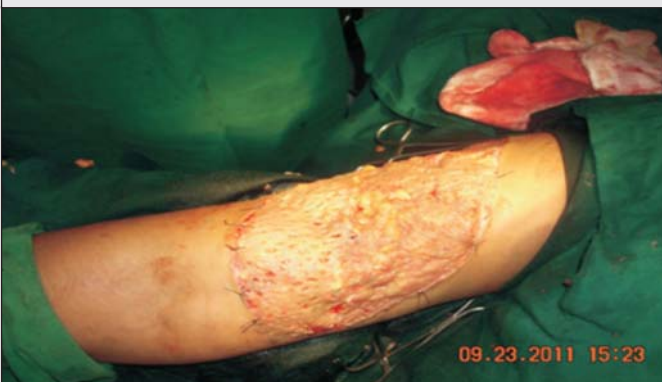

Figure - 3 : Photomicrograph shows stratified squamous keratinized epithelium, subepithelial grenz zone and the tumour mass beneath. [H&amp;e40x]



#### DISCUSSION:

Leiomyoma is a benign smooth muscle tumor<sup>[2]</sup> and cutaneous leiomyomas comprise about 5% of it.<sup>[3]</sup> The dermis contains smooth muscle fibres in the arrector pili muscles, in the walls of dermal blood vessels and in the dartos muscle of the scrotum, vulva, nipple and areola. Smooth muscle is recognised histologically by spindle shape, eosinophilic, fibrillary cytoplasm and blunt ended

Figure - 4 : Photomicrograph showing interlacing bundles of smooth muscle cells. Entrapped adnexal structures and adipocytes seen [H&amp;E100X]

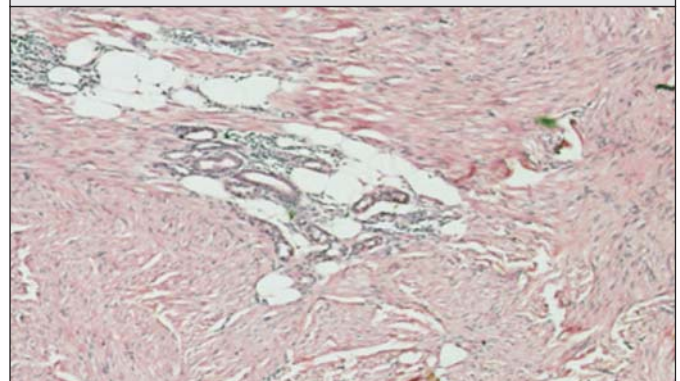
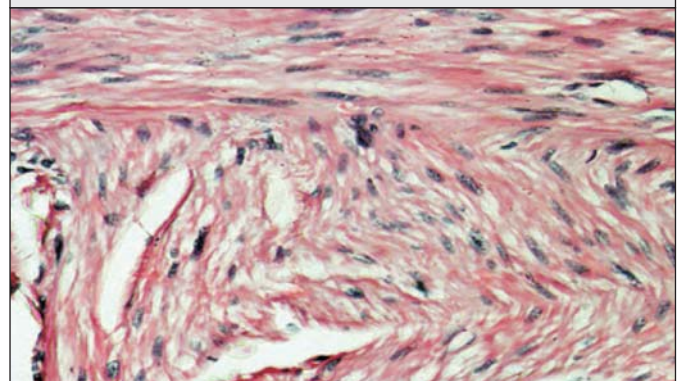


Figure - 5 Photomicrograph showing interlacing bundles of spindle shaped cells having "cigar shaped" nuclei. Arrow paranuclear glycogen vacuole [H&amp;E400X]



oval, "cigar shaped" nuclei. On immunohistochemical staining, cells express smooth muscle actin and the muscle specific intermediate filament desmin.

In one study, the 10 yr incidence was 0.04% with the majority of lesions occurring in women.<sup>[4]</sup> Most leiomyomas are acquired; however, familial inheritance patterns have been described. Especially noteworthy are patients with multiple piloleiomyomas, mostly starting in early adulthood, these patients present with increasing number of tumors developing as many as 100 to 1000 lesions. Transmission appears to be autosomal dominant with variable penetrance. Women with multiple piloleiomyomas, may also develop uterine leiomyomas, an entity termed multiple cutaneous and uterine leiomyomas also known as familial leiomyomatosis cutis et uteri or Reed Syndrome.<sup>[5]</sup> In addition, in some families with multiple cutaneous leiomyomas and uterine leiomyomas have been shown to cluster renal cell cancer

and this has been termed as hereditary leiomyomatosis and papillary renal cell cancer.<sup>[6]</sup> In our case we have not encountered any renal pathology.

Recently a loss of function mutation in the gene encoding fumarate hydratase on chromosome 1q 42-3-43 has been shown to predispose individuals to these conditions.<sup>[7]</sup> Fumarate hydratase is considered to be a tumor suppressor gene

Cutaneous leiomyomas are divided into three subsets:

Solitary or multiple piloleiomyomas originating from the arrector pili muscles, genital leiomyomas originating from the mammary, dartos, labial or vulval muscles and angioleiomyomas originating from vascular smooth muscles, the most common presentation is that of multiple piloleiomyomas.<sup>[2]</sup> Individual lesions range in size from several millimetres to 1cm and are usually reddish brown papulonodules. The extremities, trunk, sides of face and neck are the common location. Patient with piloleiomyomas often have pain that may be spontaneous or secondary to cold, pressure or emotion.<sup>[8]</sup> Possible explanation for this phenomenon include pressure of the tumor on local nerve fibres and abnormal contraction of smooth muscle fibres through nor epinephrine release at the postganglionic nerve fibres acting on alpha receptors of arrector pili muscle.

Cutaneous leiomyomas doesn't regress spontaneously and they cause considerable amount of pain and disfigurement which effect the patients activity and self esteem. There doesn't appear to be risk of malignant transmission into leiomyosarcoma. Occasionally leiomyomas are associated with polycythemia. This may be due to erythropoietin like activity of leiomyomas, which has been demonstrated in tumor extracts.<sup>[9]</sup>

Excision with or without skin grafting is the treatment of choice with a risk of recurrence. Other treatment option is Carbon dioxide laser ablation.<sup>[10]</sup> Cryotherapy and electrocoagulation are less effective alternatives. The medical treatment options include nitroglycerine, phenoxybenzamine, nifedipine, gabapentine or topical analgesics.<sup>[11,12]</sup>

We managed our case with excision of the cutaneous

lesions and primary split skin graft for confluent lesions and excision and primary suturing for solitary lesions. At one year follow up she was symptom free and free of recurrence.

## REFERENCE

1. Alam NA, Bevan S, Churchman M, et al. Localisation of a gene (MCUL1) for multiple cutaneous leiomyomata and uterine fibroids to chromosome 1q 42-3-q43. *Am J Hum Genet.* 2001;68:1264-9.
2. Holst VA, Junkins-Hopkins JM, Elenitsas R cutaneous smooth muscle neoplasms; clinical features, histologic findings and treatment options. *J Am Acad Dermatol.* 2002;46:477-90.
3. Spencer JM, Annonette RA. Tumors with smooth muscle differentiation. *Dermatol Surg* 1996;22:761-8.
4. Fernandez-Pugnaire MA, Delgado-Florencio V: Familial multiple cutaneous leiomyomas. *Dermatology* 191:295, 1995 PMID: 85739251
5. Burden PA et al: Piloleiomyoma arising in an organoid nevus: A case report and review of the literature. *J Dermatol Surg Oncol* 13:1213, 1987 PMID: 33123321
6. Ann Rothman, Gladys Glenn, Lynda Choyke, Ramapras da sinivisan et. al. Multiple painful cutaneous nodules and renal mass. *J Am Acad Dermatology.* Vol.55, NO 4:683-686.
7. Alam NA et al: Fumarate hydratase mutations and predisposition to cutaneous leiomyomas, uterine leiomyomas and renal cancer. *Br J Dermatol* 153:11,2005.
8. Thyresson HN, Su WP: Familial cutaneous leiomyomatosis. *J Am Acad Dermatol* 4:430, 1981 PMID: 72291471
9. Venencie PY et al: Multiple cutaneous leiomyomata and erythrocytosis with demonstration of erythropoietic activity in the cutaneous leiomyomata. *Br J Dermatol* 107:483, 1982 PMID: 71264551
10. Christenson U et al: Treatment of multiple cutaneous leiomyomas with CO<sub>2</sub> laser ablation. *Dermatol Surg* 26:319, 2000 PMID: 107598171
11. Alam M et al: Gabapentin treatment of multiple piloleiomyoma-related pain. *J Am Acad Dermatol* 46:s27,2002.
12. Batchelor RJ et al: successful treatment of pain in two patients with cutaneous leiomyomata with the oral alpha-1 adrenoreceptor antagonist, doxazosin. *Br J Dermatol* 150:775,2004.