

SUPERIOR MESENTERIC ARTERY ARISING FROM CELIAC AXIS ASSOCIATED WITH AN ACCESSORY LEFT HEPATIC ARTERY FROM LEFT GASTRIC ARTERY- A RARE ANATOMIC VARIATION

Chitra P.S.¹, Anandhi V.²

ABSTRACT

The superior mesenteric artery originates from the aorta 1cm below the coeliac trunk, at the level of L 1-2 intervertebral disc. It lies posterior to the splenic vein and the body of the pancreas.¹ We describe an extremely rare anatomic variant-celiomesenteric trunk (CMT) that consists of celiac and superior mesenteric arteries having a common origin from the aorta, and also an accessory left hepatic artery(ALHA) arising from the left gastric artery, in the same case. Knowledge about the variant anatomy is essential to accomplish surgical, oncologic or interventional procedures including lymphadenectomy around hepatosplenic trunk, chemoembolization of liver malignancies, all of which can potentially create significant morbidity because of the large visceral territory supplied by single vessel.²

KEY WORDS : Celiomesenteric trunk, superior mesenteric artery, celiac artery, accessory left hepatic artery, left gastric artery, variation.

INTRODUCTION

The primitive fetal blood supply is initially a dual one, with double aortas and both a ventral and dorsal arterial supply to abdominal viscera. During subsequent differentiation, much of this dual vascular supply regresses. Varying degrees of persistence of certain portion of dual blood supply account for the many variations that are seen in the mesenteric circulation³. Vitelline arteries are initially a number of paired vessels supplying the yolk sac. Gradually they fuse and form the arteries located in the dorsal mesentery of the gut. In the adult, they are represented by the celiac, superior mesenteric, and inferior mesenteric arteries. These vessels supply the derivatives of foregut, midgut and hindgut, respectively.⁴

The celiac trunk usually arises from the aorta at the level of T₁₂ and after a short course, divides into left gastric, common hepatic and the splenic arteries. The superior

mesenteric artery is the 2nd ventral branch of abdominal aorta at the level of L1. The celiac and superior mesenteric arteries have a common origin (CMT) in less than 1% of all abdominal vascular anomalies, and it is estimated to have an incidence of 0.25%.^{3,5} R.M.Jones & K.J.Hardy et al reported that the occurrence of left hepatic artery from left gastric artery is about 15%.⁶

CASE REPORT

During routine dissection classes for MBBS students at K.A.P.V. Govt. Medical College, Trichy, in a 50 year old female cadaver, we found the celiac and superior mesenteric arteries having a common origin from the abdominal aorta-celiomesenteric trunk. From this trunk, the branches of the celiac artery, namely the common hepatic artery, the left gastric artery, the splenic artery and the superior mesenteric arteries were seen branching out in a cruciform manner. The common hepatic artery, after giving the right gastric artery, trifurcated into right and left hepatic arteries and gastro duodenal artery. The left gastric artery was unusually large and an accessory left hepatic artery was found arising from it and entering into the left lobe of liver. [Fig.1]

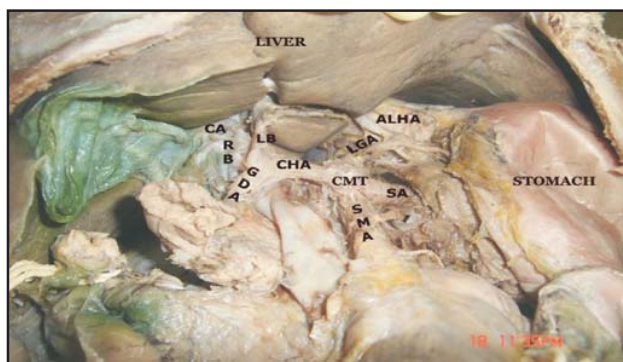


Fig 1—Showing Common celiomesenteric trunk from abdominal aorta and the accessory left hepatic artery from left gastric artery.

CMT- Celiomesenteric trunk, SMA-Superior mesenteric artery
SA-Splenic artery, LGA-Left gastric artery, ALHA-Accessory left hepatic artery, CHA-Common hepatic artery, RB-Right branch, LB-Left branch, GDA-Gastroduodenal artery, CA-Cystic artery

¹Associate Professor, ²Assistant Professor, Department of Anatomy, K.A.P.V. Govt Medical College, Trichy, Tamil Nadu.

DISCUSSION

Celiac and superior mesenteric arteries having a common origin from the aorta account for less than 1% of all abdominal vascular anomalies. It is estimated to have an incidence of 0.25%.^{7,8,9} When this anomaly is found, it has wide ranging implications. A patient with CMT is deprived of some of the protective benefits of dual origin vessels with multiple mutually supporting anastomoses.¹⁰ Occlusive disease of a CMT would logically produce symptoms of acute or chronic mesenteric ischemia. The redundancy between celiac and superior mesenteric arterial occlusion is non-existent in case of a CMT, and a proximal stenosis affecting this vessel would have serious ischemic consequences to the intestine.⁹ The compression of CMT should be borne in mind in cases of recurrent abdominal pain and weight loss.

In embryonic and early fetal life, the hepatic artery arises from the left gastric artery (67% of 56 individuals).¹¹ This condition rarely persists, or the right or left hepatic arteries may arise from other vessels, the former from the superior mesenteric and latter from the left gastric.

The accessory left hepatic artery from left gastric passing to the right in the lesser omentum to the porta hepatis is easily damaged in partial gastrectomy.

Lurie¹² reported a case of left lobe hepatic necrosis after severing the accessory left hepatic artery. An aberrant left hepatic artery that feeds a wide area within the liver may cause postoperative liver dysfunction when that artery is severed during surgery. So the knowledge of ALHA is essential for surgeons operating in the vicinity of the liver.

It is important to understand the vascular anatomy of a region in planning a surgical intervention and the

evaluation and management of the various disease processes that may affect the gastrointestinal system.

CONCLUSION

Knowing the existing vascular anomalies enhances the insight regarding that area and helps to prevent mistakes due to a lack of awareness during surgeries like pancreaticoduodenectomy.

REFERENCES

1. Standring S, Ellis H, Healey JC, Johnson D, Williams A, Collins P, et al. Gray's Anatomy. The Anatomical Basis of Clinical Practice. Elsevier Churchill Livingstone Ltd, Spain. 2005; 39:1118.
2. Losanoff JE, Millis JM, Harland RC, Testa G. Hepato-Spleno-Mesenteric Trunk. J Am Coll Surg. 2007;204:511.
3. Reuter SR, Redman HC, Cho KJ, Manke D, Tumors. In Gastrointestinal Angiography. Philadelphia. Pu: Sanders. 1986; 3:162-171.
4. Sadler TW. Langman's Medical Embryology. 2006;10:183.
5. Petsavage J.M. Maldjian P. Celiomesenteric Trunk: Two Variants Of A Rare Anomaly. Austraias Radiol: 2007; 51(Suppl) B: 306-B309.
6. R.M.Jones & K.J.Hardy et al. Hepatic Artery Anatomy In Relation To Reconstruction To Liver Transplantation Some Unusual Variations. Aust Nz.J Surg.1994;64:437-403.
7. Michels NA, Siddharth.P, Cornblith.P.L, Parke.WW. Routes Of Collateral Circulation Of The Gastrointestinal Tract As Ascertained In A Dissection Of 500 Bodies. Int. Surg.1968;49;8-28 .
8. Fontaine R, Pietrij, Tongio J, Negreiros L. Angiographic Study Of Anatomical Variations Of Hepatic Arteries Based On 402 Specialised Examinations Angiology. 1970 Feb;21(2):110-3.
9. Lawler LP, Fishman EK. Celiomesenteric Anomaly Demonstration By Multidetector CT And Volume Rendering. J. Comput. Asst. Tomogr. 2001;25:802-4.
10. Ailawadi G, Cowles RA, Stanley JC, Eliason JL, Williams DM, Colletti LM, et.al. Common Celiomesenteric Trunk Aneurismal And Occlusive Disease. J. Vasc. Surg. 2004;40:1040-3.
11. Godlewski G, Hedon B, Castel C. Contribution a l'etude de l'origine de l'artere hepatique chez l'embryon et le foetus. Bull Assoc Anat Nancy. 1975; 59: 411-418.
12. Lurie AS. The Significance Of The Variant Left Accessory Hepatic Artery In Surgery For Proximal Gastric Cancer. Arch Surg. 1987; 122 (6): 725-728.